

## ORIGINAL ARTICLE

**Protective Effect of Aqueous Neem Leaf Extract on Erythromycin Induced Histomorphological Changes on Hepatocytes of (Albino Wistar) Rats**Nausheen Jamshed<sup>1</sup>, Iffat Raza<sup>1\*</sup>, Nadia Rashid<sup>2</sup>, Lubna Akhter<sup>2</sup>, Mubina Lakhani<sup>3</sup>, Aqiba Islam<sup>4</sup>**ABSTRACT****Objective:** To determine the protective effect of aqueous Neem leaf extract-induced hepatotoxicity by Erythromycin.**Study Design:** Laboratory-based Experimental study.**Place and Duration of Study:** The study was conducted at the Department of Anatomy and Animal House of Baqai Medical University (BMU) Karachi, Pakistan from January 2019 to March 2019.**Materials and Methods:** A total of 80 albino Wistar male rats were randomly divided into 4 groups. Control group, marked as Group A with no interventions. Only Erythromycin was administered to the rats in group B. Erythromycin and an aqueous extract of neem

leaves were administered to group C rats. Group D only received an extract of aqueous neem

leaves. Animals' body weight was noted both before and after experiments. Liver weight was also measured after 14 days when the animals were sacrificed.

**Results:** Histopathological changes in group B include loss of architecture, portal vein observed with congestion, and hemorrhages. In Group C, histopathological changes showed hepatocytes with slightly disturbed and mild congestion with decreased sinusoidal spaces; however, Group A and Group D observed normal hepatocyte architecture.**Conclusion:** According to the current study, Erythromycin-induced oxidative stress and hepatocyte damage were markedly reduced by aqueous neem leaf extract, which is a powerful antioxidant.**Keywords:** *Erythromycin, Hepatotoxicity, Hepatocytes, Hemorrhages.***How to cite this:** Jamshed N, Raza I, Rashid N, Akhter L, Lakhani M, Islam A. Protective Effect of Aqueous neem leaf Extract on Erythromycin Induced Histomorphological Changes on Hepatocytes of (Albino Wistar) Rats. 2023; 4(3): 325-333. doi: <http://doi.org/10.37185/LnS.1.1.354>

This work is licensed under a Creative Commons Attribution-NonCommercial 4.0 International license.

(https://creativecommons.org/licenses/by-nc/4.0/). Non-commercial uses of the work are permitted, provided the original work is properly cited.

**Introduction**

The liver is a vital organ to maintain homeostasis in

<sup>1</sup>Department of Anatomy

Karachi Institute of Medical Sciences, Karachi, Pakistan

<sup>2</sup>Department of Anatomy

Foundation University Islamabad Campus, Islamabad, Pakistan

<sup>3</sup>Department of Anatomy

Ziauddin University Karachi, Karachi, Pakistan

<sup>4</sup>Department of Anatomy

Sialkot Medical and Dental College, Sialkot, Pakistan

Correspondence:

Dr. Iffat Raza

Associate Professor, Anatomy

Karachi Institute of Medical Sciences, Karachi, Pakistan

E-mail: [razaiiffat2@gmail.com](mailto:razaiiffat2@gmail.com)

Funding Source: NIL; Conflict of Interest: NIL

Received: Feb 02, 2023; Revised: Mar 06, 2023

Accepted: Mar 08, 2023

the body and perform various functions like digestion, biosynthesis, and detoxifying poisonous substances. The liver consists of soft parenchyma, extremely vascular, pinkish brown, friable and a smooth, even surface.<sup>1</sup> Under a microscope, each lobe of the liver consists of a hepatic lobule. Within these unevenly hexagonal hepatic lobules, around the central vein, hepatocytic plates are arranged in a radiating manner and are typically organized into cords, which are one or two cells separated by sinusoids.<sup>2</sup>

A widely used and safe antibiotic among the macrolide group is Erythromycin.<sup>3</sup> It has been used for the treatment of numerous infectious diseases for more than 50 years and is also valuable for the cure of several infections, including tonsillitis,

urinary tract infections, bronchopneumonia, mastitis, arthritis, and lymphadenitis.<sup>4</sup> It is an effective prokinetic agent in the cases of gastroparesis due to scleroderma and diabetes mellitus.<sup>5</sup> Erythromycin is a suitable drug to treat and prevent per prosthetic membrane infection and is also given for the cure of chorioamnionitis and premature preterm rupture of membranes (PROM),<sup>6</sup> however when erythromycin stearate was given orally to rats for 14 days daily dose of 100 mg/kg body weight which results in significant liver damage and hepatotoxicity.<sup>7</sup>

Azadiachta is derived from Persian language with the meaning of "Noble tree". *Azadirachta indica* (Neem) is an effective and multipurpose evergreen tree which has been used for decades in agriculture and medicine.<sup>8</sup> It consists of many powerful components as limonoids is one of the important bioactive compounds, the other main components are alkaloids, flavonoids, and meliantriol, followed by nimbin, saladin, steroids, carotenoids, ketones, phenolic compound, nimbin, salanin, valassin, meliacin, reducing The bioactive ingredients like sterol, peptides, flavonoids, alkaloids, glycosides, phenols and tannins comprises medicinal properties.<sup>9</sup> It has been well-known that Neem extract has shown hepatoprotective properties in cases of paracetamol intoxication due to its antioxidative activity.<sup>10</sup> Its extract improves mononuclear phagocyte systems, cellularity, immune stimulant activity, and hepatoprotection.<sup>11</sup> The hepatoprotective dose of neem extract is 500mg/kg body weight, reducing hepatocellular necrosis and protecting against liver damage while restoring the liver to its normal functions.<sup>12</sup>

### Materials and Methods

This Experimental study was conducted in Baqai Medical University from Jan 2019 to Mar 2019 permitted by ethical committee BMU-EC/2017-05. Eighty (80) adult male Albino Wistar rats, 13–14 weeks old, weighing 180–200g, were obtained from animal house in a controlled setting at 30 °C with an average of 14 days and 10-night cycles, the animals were housed in a plastic cage with five rats per cage. The rats were given standard food and water. Acclimatization of rats for about 10 days was assured before the start of the study.

Erythromycin tablets (erythrocin R) 500 mg made by Indus Pharma from the pharmacy in Malir Cantt, Karachi was purchased. Aqueous Neem leave extract were prepared at Pakistan Council Scientific & Industrial Research (PCSIR) Karachi. Only healthy, young rats were used in the experiment. Rats who were weak, old, or female were kept out of the experiment.

### Participant Selection Strategy

Eighty (80) healthy young males' rats were included in this study

### Data Collection Strategy

**Grouping:** Eighty (80) male rats were randomly placed into four groups of twenty (20) each as "A," "B," "C," and "D."

**Group A** served as the control group, it received no treatment and was given a regular diet.

**Group B** was received Erythromycin only for 14 days at a dose of 100mg/kg (body weight) via gastric gavage.

**Group C** received erythromycin 100 mg/kg (body weight) and aqueous Neem Extract 500 mg/kg (body weight) simultaneously via gastric gavage.

**Group D** received only aqueous Neem Extract 500 mg/kg (body weight) via gastric gavage.

All of the animals were weighed at an electronic weighing machine before the start of the study and then repeated every third day. Rats were housed in plastic cages.

Animals were weighed for final weights following the last dose and were given either anesthesia before being placed in a glass container. Given a midline longitudinal incision starting at the manubrium on the dissection board. To reveal the organs, extend the sterni down to the lower abdomen.

### Statistical Analysis

Complete data were analyzed using SPSS (statistical package for social sciences) version 23. Arithmetic means were estimated for each quantitative variable, and results were presented as (Mean  $\pm$  SE) mean  $\pm$  standard error. ANOVA (post hoc Tukey's) was applied to measure significant difference within groups. *P* value is less than or equal to 0.05, it is considered markedly significant with 95% confidence interval.

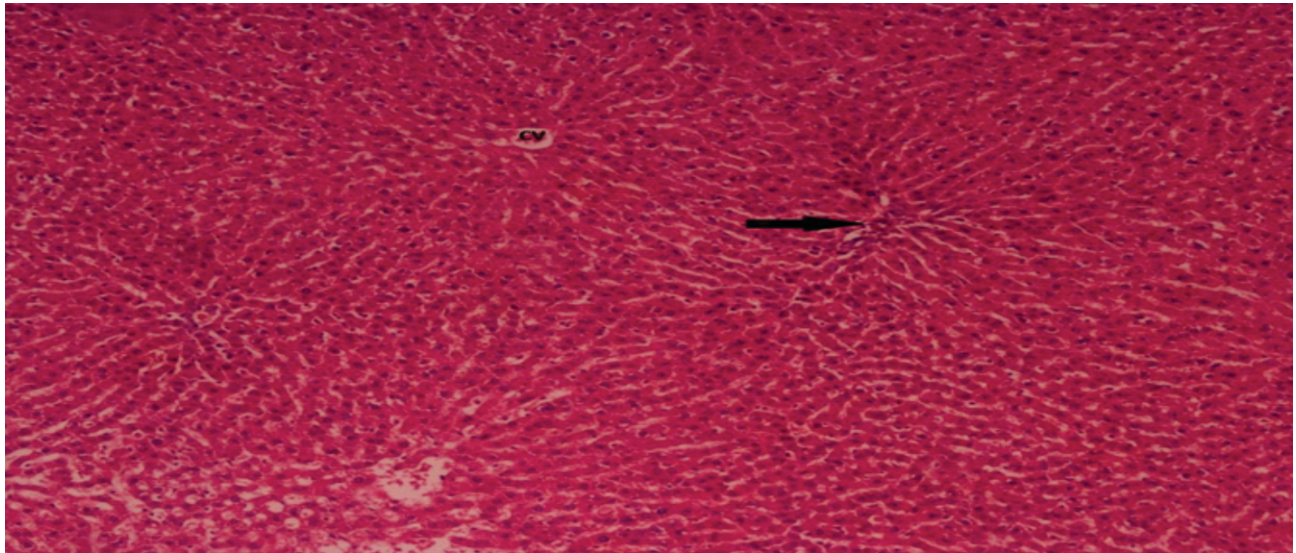
### Results

#### Control Group A

The normal morphological and histological structure of the hepatic lobules is seen with hematoxylin and eosin (H and E) stained histological examination of liver slices from control group A at 40X and 100X magnification. The liver consists of quadrilateral shaped lobules. Each lobule has a hexagonal form and within each lobule are hepatocytes that surround the central vein and are arranged into cords

that are divided by sinusoids. Kupffer and endothelial cells border the sinusoids. Hepatocytes are characterized as polyhedral cells with regularly spaced acidophilic cytoplasm surrounding their darkly pigmented nuclei. Hepatocytes that had been binucleated. Bile duct, hepatic artery, and portal vein are all part of the portal tract (Figure 1).

Histopathological Photograph of Group A (control)



**Fig 1: Control Group a -100X (H&E)**

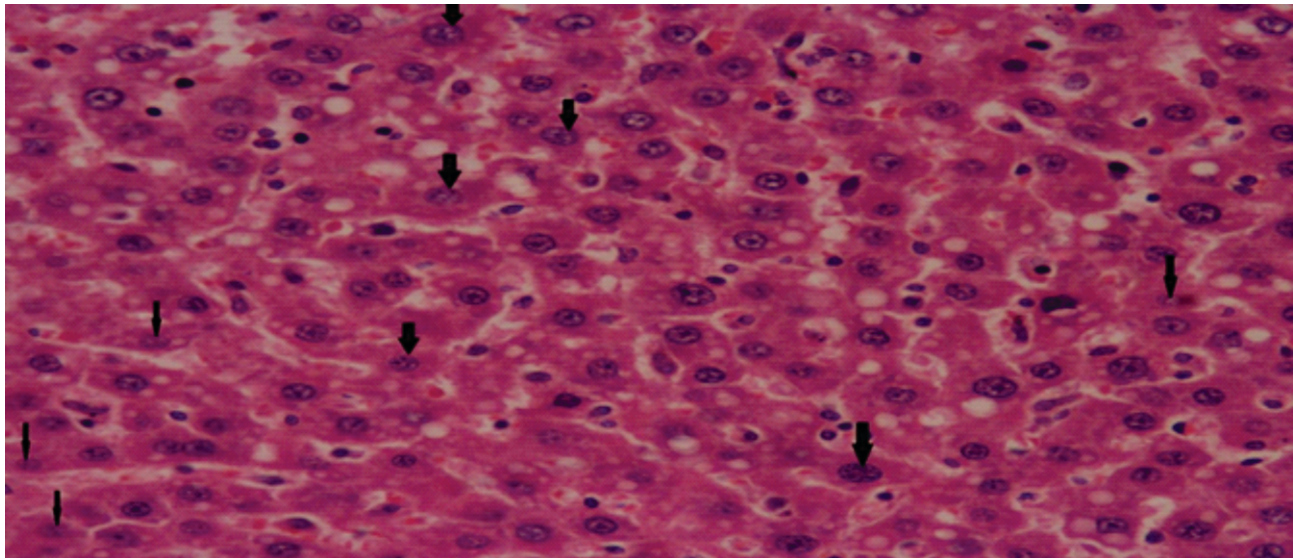
rats presenting normal hepatic lobules, arrow represent portal triad

#### **Group B Erythromycin Treated Rats**

The liver of Albino rats was cut into sections, and the sections were examined histopathological and morphologically using H and E staining at 40X and

100X objective magnification. Hepatocytes displayed severely vacuolated cytoplasm. Numerous nuclei showed fragmentation, pyknosis, karyolysis, and karyorrhexis were seen as macro and micro-vesicular steatosis (Figure 2).

Histopathological Photograph presenting

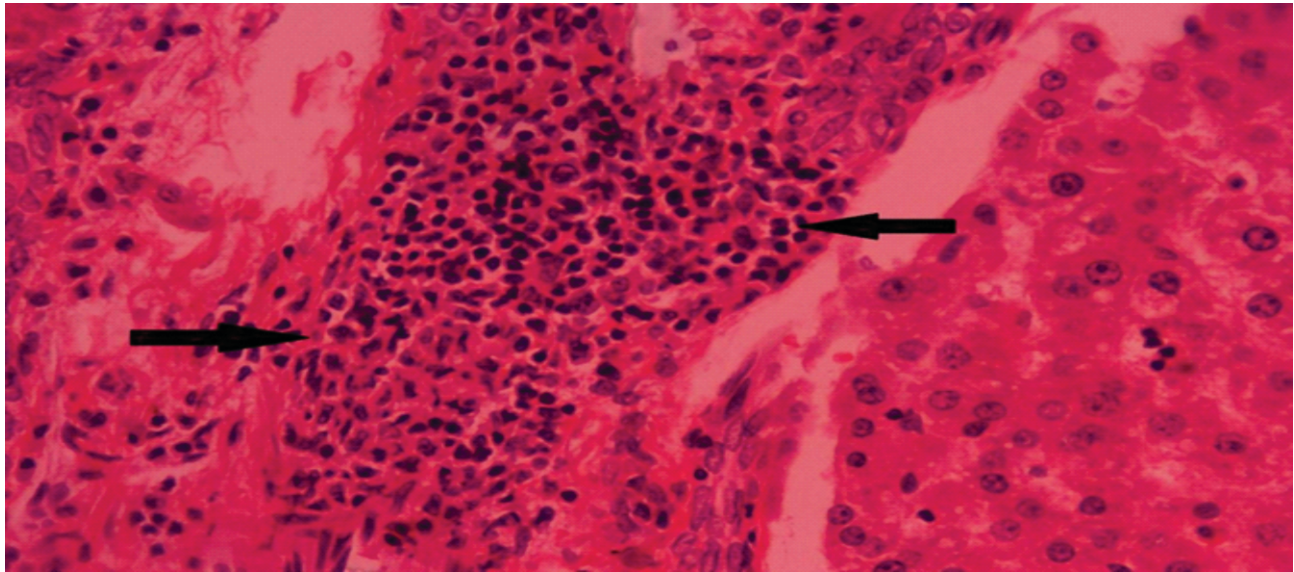


**Fig 2: Group B (Erythromycin Treated Rats)-100X (H&E)**



karyorrhexis (fragmentation of nucleus) thick arrows and karyolysis (fading of nucleus) thin arrows  
The portal vein was enlarged and congested, and

mononuclear infiltration accumulated around and within the portal triad along lymphocytic infiltration (Figure 3).

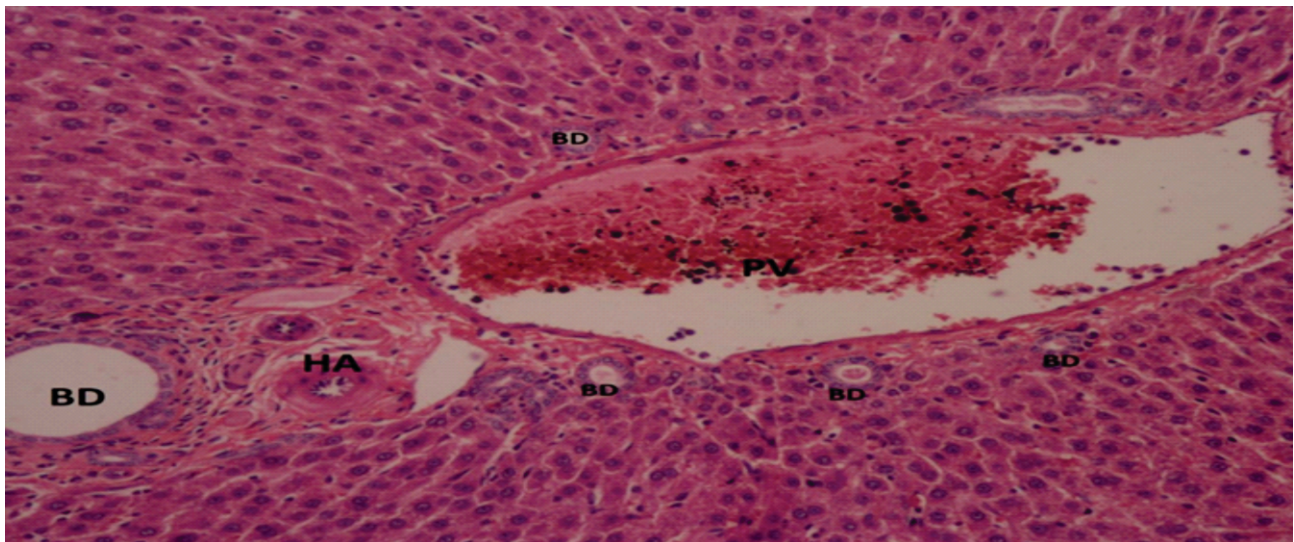


**Fig 3: Group B (Erythromycin Treated Rats)-100X (H&E)**

Histopathological Photograph presenting moderate lymphocytic infiltration in portal triad (arrows) Group B showed extensive necrosis and degenerative changes in different areas. Distorted parenchyma with deformed hepatic cord. Congested

and dilated central veins were observed. The central vein presented with mononuclear cells. Liver parenchyma hemorrhages are also seen (Figures 4 and 5).

Histopathological Photograph presenting portal



**Fig 4: Group B (Erythromycin Treated Rats)-100X H&E**

triad, congested portal vein (PV) hepatic artery (HA) and bile duct (BD) along small bile ductule  
Histopathological Photograph presenting tissue necrosis with acidophilic cytoplasm (thick broad arrows) and vesicular nuclei with central vein

congestion

Significant congestion is indicated by vacuolization and larger sinusoidal gaps. Hepatocyte necrosis and ballooning are evident in (Figure 6).

Histopathological Photograph presenting ballooning



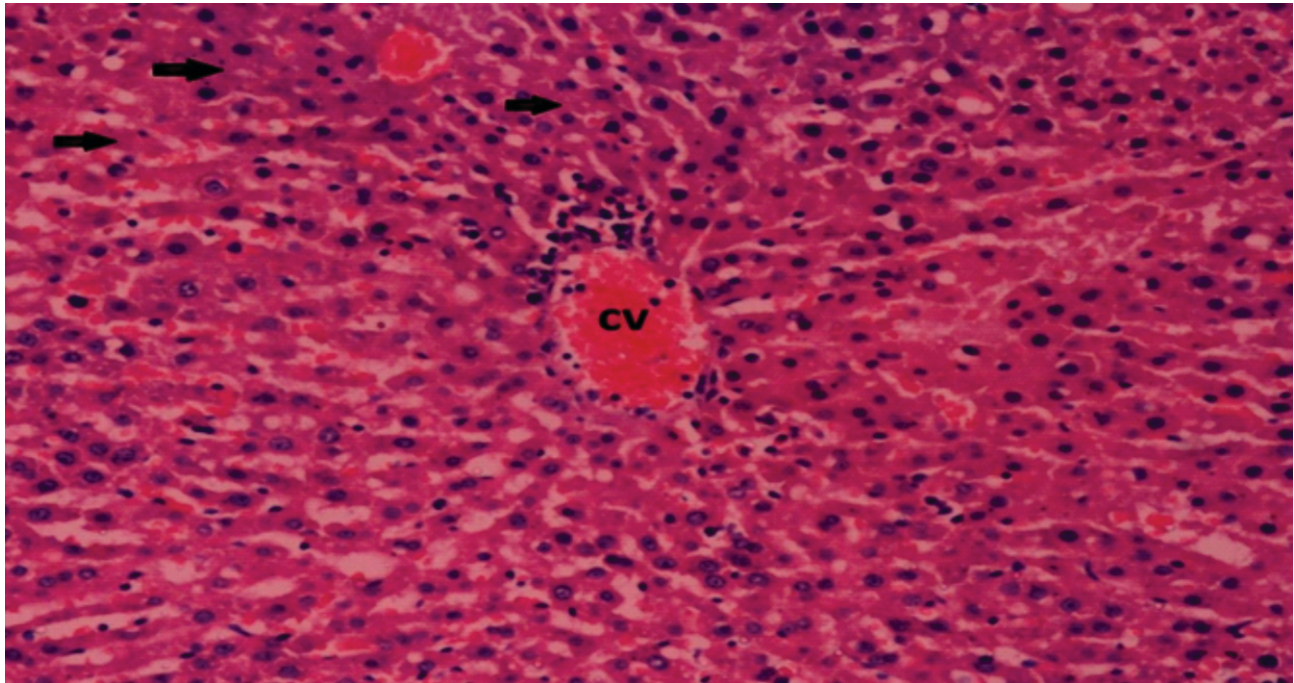


Fig 5: Group B (Erythromycin Treated Rats)-100X (H&E)

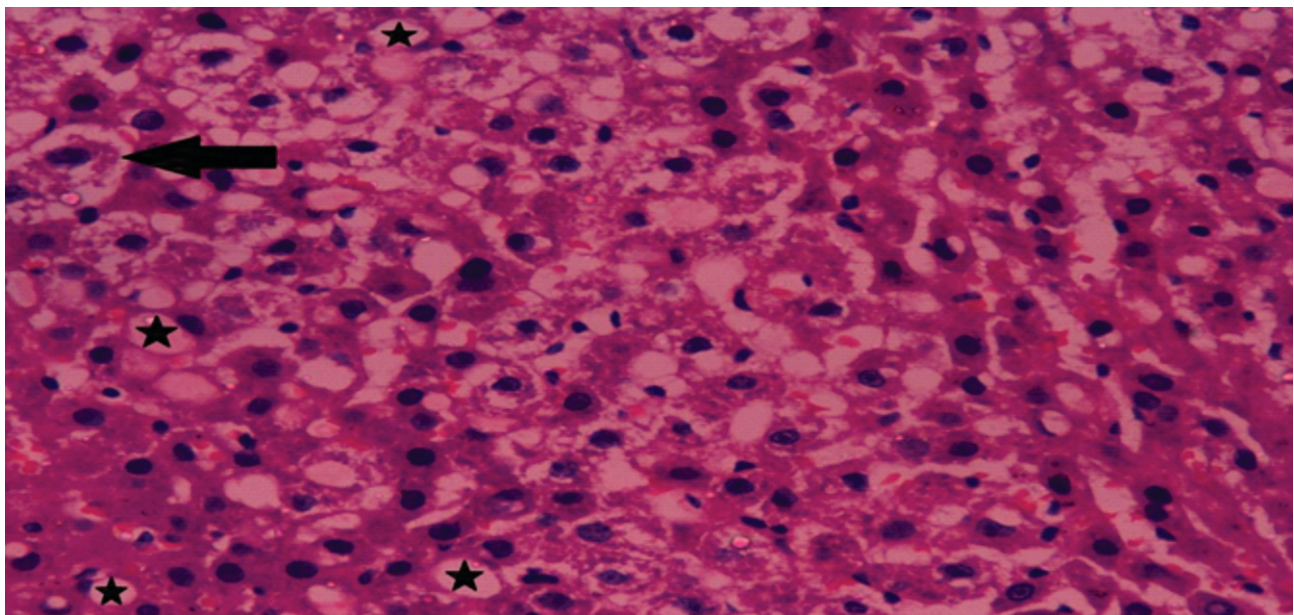


Fig 6: Group B (Erythromycin Treated Rats)-100X (H&E)

of hepatocytes (arrow) and stars shows vacuolization  
**Group 'C' (Erythromycin Plus Neem Treated Rats)**

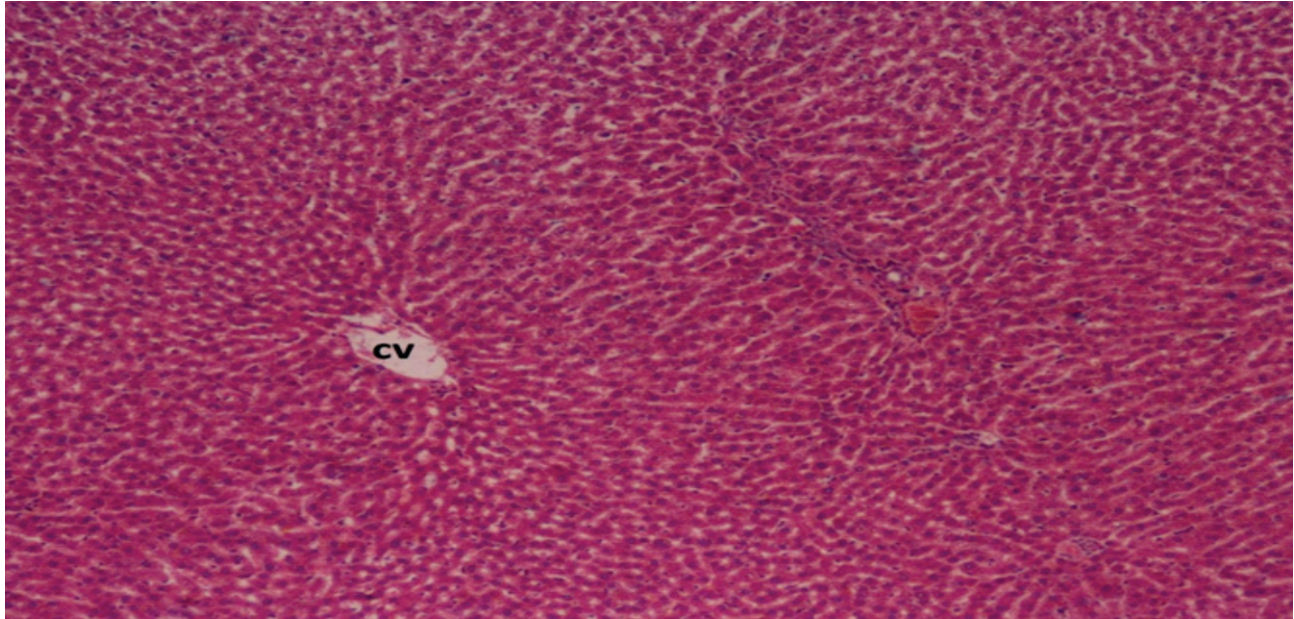
To evaluate the histopathological and histomorphology examinations of H and E stained at 40X and 100X magnification of group C animals, slide were observed with less hepatic parenchymal necrotic tissue (figure 7).

Histopathological Photograph presenting preservation of slight disturb architecture with mild

congestion and decreased sinusoidal spaces shows near normal hepatic architecture

Hepatic lobule radiating cords were seen to be slightly distorted. Additionally, the portal triad showed a mildly congested central vein with minor infiltration of mononuclear cells and some areas of hemorrhages were reported and sinusoids showed minimal dilation, the hepatocytes showed slightly vacuolated cytoplasm and very few hepatocytes





**Fig 7: Group C (Erythromycin And Neem Treated Rats)-100X (H&E)**

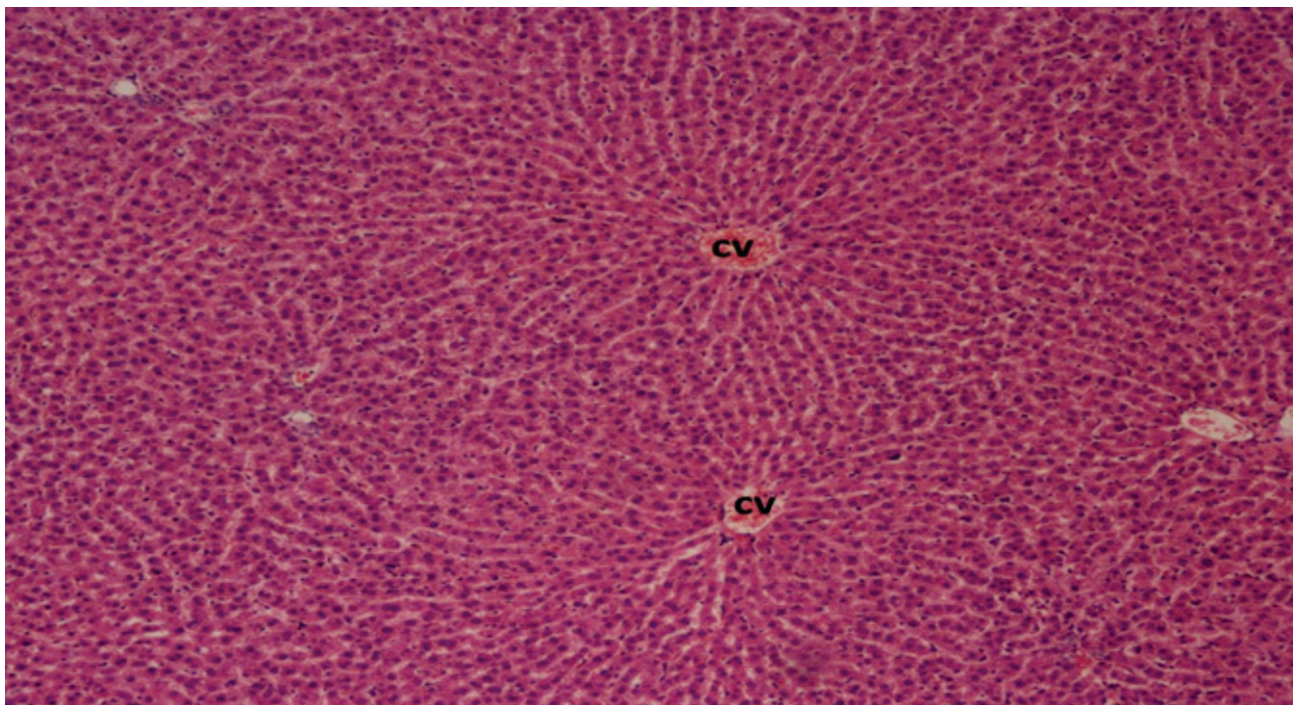
contained nuclei fragmentation.

#### **Positive Control Group "D"**

Sections of the liver from albino rats were examined for histomorphology using H&E staining at 40X and 100X magnification. Group D animals showed normal histological and morphological structure of hepatic lobules. Each lobule of the liver appears to be normal and the bile canaliculi and central vein are all

present. Sinusoids appeared normal and no dilatation was observed. Sinusoids were lined with endothelial cells along Kupffer cells. Polyhedral hepatocytes distributed uniformly. Some hepatocytes were binucleated. Portal triad observed normal containing hepatic artery, bile ducts and portal vein (Figure 8).

Histopathological Photograph displayed normal



**Fig 8: Group D (Positive Control)-100X (H&E)**



architecture of liver with branching pattern hepatocytes around central vein and portal triad appeared normal with no congestion and infiltration

## Discussion

Liver damage can result from exposure to toxic chemicals, alcohol use, drugs and viral infections. Most liver damage is related with the redox imbalance and oxidative stress in the body.<sup>13</sup>

Erythromycin is a macrolide antibiotic with a long history of usage to eliminate several types of infections caused by bacteria. It acts as a bacteriostatic agent against several gram-positive microorganisms. Liver injury from erythromycin treatment is rarely reported clinically but due to longer usage of Erythromycin has been reported as one of the most frequent causes of drug-induced liver damage.<sup>14</sup>

Many components of neem leaves such as nimbidine, also had anti-inflammatory activity.<sup>15</sup> Additionally, Doaa Ezz-Din et al. used the same dose of *A. indicia* leaf extract in his study. In this case, aqueous neem extract showed a hepatoprotective effect that restored the disturbed architecture of liver to its normal structure. The authors concluded that it may be quercetin in neem leaves with antioxidant activity, increasing intracellular concentrations of glutathione and inhibiting lipid peroxidation by scavenging free radicals.<sup>16</sup>

The study conducted by Faiza Aslam et al. also stated similar results in her study, concluding that neem leaf extract showed hepatoprotective effects and practical uses of neem leaf in the standard system of medicine.<sup>17</sup>

In our present study, albino rats treated with Erythromycin generated progressive changes for 2 weeks resulting in hepatocyte damage. A marked loss of general architecture was observed in the liver lobules which is consistent with studies by Michael D. Leise et al. who stated that Erythromycin caused central necrosis, hepatocellular degeneration and portal vein inflammation at high doses or long-term use.<sup>18</sup>

According to Preeti Singh, this may be due to free radical generation and oxidative stress from Erythromycin.<sup>19</sup> Observations were noted that there was hepatocellular necrosis with marked lobular

inflammation of predominantly plasma cells with lymphocytes and eosinophils. In addition, the cytoplasm of hepatocytes exhibited micro vesicular steatosis with hyperchromatic nuclei of small lipid droplets. In macro vesicular steatosis, large fatty vacuoles replaced the cytoplasm and shift the nucleus towards the periphery. Similarly, Lopez Panqueva et al., who reported the mechanism of liver injury caused by Erythromycin, explained the causes of micro- and macro steatosis due to disruption of mitochondrial oxidation. This is consistent with Abdel et al. who found that cholestasis, hepatitis and initiation of hepatocellular damage occurred in laboratory animals treated with Erythromycin.<sup>20,21</sup>

Giovanni Taranto et al. also identified zone 3 marked necrosis, mononuclear infiltration, and edematous degeneration due to erythromycin toxicity.<sup>22</sup> With long-term use of Erythromycin, the liver showed sinusoidal dilatation, enlargement and obstruction of the portal and central veins. These results were similar with Anne M. Larson et al. results, which defined equivalent changes in the hepatic vein.<sup>23</sup>

In rats given Erythromycin and aqueous neem leaf extract, liver tissue alteration showed decreased necrotic, pyknotic and nuclear degenerative lesions in contrast to erythromycin-treated rats. Neem leaf antioxidant activity reduced erythromycin-induced hepatotoxicity. These conclusions suggest that aqueous neem extract prevented paracetamol-induced hepatotoxicity due to its rich content of flavonoids, potent antioxidants which contributed to the hepatoprotective activity due to the anti lipid peroxidation activity of neem leaves. It is consistent with a study by Guru Siddappa KS et al.<sup>24</sup>

Mac Donald Idu et al. also reported that liver lobular architecture was maintained normally after animals were co-administered with neem extract and carbon tetrachloride.<sup>25</sup>

## Conclusion

The current study determined that the Erythromycin has significant hepatotoxic effects on albino wistar rats. The noticeable changes (histopathological) produced by the Erythromycin were magnificently improved by aqueous Neem leave extract (*Azadirachta indica*). Aqueous Neem leave extract is powerful antioxidant as it acts as a hepatoprotective

agent. Advance studies are required to assess the splendid use of Neem leaves, against Erythromycin induced hepatotoxicity.

### Acknowledgment

Professor Kishwar Sultana and Dr. Sadia, senior scientific officer at (PCSIR) for her continuous support during this research.

### limitations

1. The present study should have been conducted on large group of animals.
2. Liver function test will be included in next phase of research.

### REFERENCES

1. Ozougwu JC. Physiology of the liver. International Journal of Research in Pharmacy and Biosciences. 2017; 4:13-24.
2. Mathew RP, Venkatesh SK. Liver vascular anatomy: A Refresher. Abdominal Radiology (NY). 2018; 43: 1886-95. doi: 10.1007/s00261-018-1623-z
3. Shafia S, Chandluri P, Ganpiseti R, Lakshmi B, Swami PA. Erythromycin uses as Broad-spectrum Antibiotic. World Journal of Pharmaceutical and Medical Research. 2016; 2: 23-6.
4. Goma A, Tohamy H. Impact of some heavy metals toxicity on behaviour, biochemical and histopathological alterations in adult rats. Advances in Animal and Veterinary Sciences. 2016; 4: 494-505. doi: 10.14737/JOURNAL.AAVS/2016/4.9.494.505
5. Aghili Dehnavi H, Amin MM, Fatehizadeh A, Movahedian Attar H, Ebrahimpour K, Bina B. Assessment of toxicity and kinetic effects of Erythromycin on activated sludge consortium by fast respirometry method. Environmental Health Engineering and Management Journal. 2021; 8: 205-14. doi: 10.34172/EHEM.2021.24
6. Li YY, Kong CW, To WW. Pathogens in preterm prelabour rupture of membranes and Erythromycin for antibiotic prophylaxis: a retrospective analysis. Hong Kong Medical Journal. 2019; 25: 287-94. doi: 10.12809/hkmj197991
7. Al-Timimi ZK, Taher TA. Hepatotoxic Impact of Erythromycin Succinate After Orally Repeated Exposure in Male Albino Swiss Mice (*Mus musculus*). The Iraqi Journal of Agricultural Science. 2020; 51: 1375-80.
8. Martínez-Romero A, Ortega-Sánchez JL, Hernández-González SI, Olivas-Calderón EH, Alba-Romero JJ. Application of neem tree in agriculture, industry, medicine, and environment: A review. African Journal of Traditional, Complementary and Alternative Medicines. 2016; 13: 191-8. doi: 10.4314/ajtcam.v13i2.23
9. Yadav DK, Bharitkar YP, Chatterjee K, Ghosh M, Mondal NB, Swarnakar S. Importance of Neem Leaf: An insight into its role in combating diseases. Yadav, Dharmendra Kumar, Yogesh P. Bharitkar, K. Chatterjee, Monisankar Ghosh, Nirup Bikash Mondal and Snehasikta Swarnaka. "Importance of Neem Leaf: An insight into its role in combating diseases." Indian journal of experimental biology. 2016; 54: 708-18.
10. Akash Gupta, Shagufta Ansari, Siddharth Gupta, Monika Narwani, Muskan Gupta, Manali Singh. Therapeutics role of neem and its bioactive constituents in disease prevention and treatment Journal of Pharmacognosy and Phytochemistry. 2019; 8: 680-91.
11. Shareef M, Akhtar MS. Neem (*Azadirachta indica*) and its potential for safeguarding health, prevention and treatment of diseases. Matrix Science Medica. 2018; 2: 04-8. doi: 10.26480/msm.01.2018.04.08
12. Patel PM, Gohil TA, Malavia V, Bhalodia YS, Shah GB. Comparative in vitro hepatoprotective activity of different extracts of *Azadirachta Indica* leaves. Journal of Pharmacy Research. 2012; 5: 122-5.
13. Nagarkar B, Kulkarni R, Bhondave P, Kasote D, Kulkarni O, Harsulkar A et al. Comparative Hepatoprotective Potential of *Tinospora cordifolia*, *Tinospora sinensis* and *Neem-guduchi*. Journal of Pharmaceutical Research International 2013; 3: 906–16. doi: 10.9734/BJPR/2013/4003.
14. Liver tox. Clinical and Research based liver injury. [Internet] Available at <https://liver.tox.nih.gov/erythromycin>
15. Terkula kpela, Theresa B. Ekanem and Amaber O. Akpantah. Protective effect of ethanol extract of neem leaves on cisplatin induced kidney damage in wistar rats. Global Advanced Research Journal of Medicine and Medical Sciences 2012; 19: 249-54.
16. Doaa Ezz-Din Mohamed S. Gabry, Abdel Razik H. Farrag, Ahmed E. Abdel Moneim. Physiological and histological impact of *Azadirachta indica* extract in a rat model of cisplatin induced hepato and nephrotoxicity. Journal of Medicinal Plants Research. 2011; 5: 5499-506.
17. Aslam F, Jamil S, Aslam MA. Antihepatotoxic Activity of Gemmotherapeutically treated Neem and alcoholic extract of Neem in Albino Rats. Pakistan Journal of Medical and Health Sciences. 2016; 10: 68-76.
18. Leise MD, Poterucha JJ, Talwalkar JA. Drug-induced liver injury. In Mayo clinic proceedings. Elsevier. 2014; 89: 95-106. doi: 10.1016/j.mayocp.2013.09.016
19. Singh P, Singh IN, Kumar S, Gupta R. Developmental Genotoxicology and genotoxicity testing guidelines: an



- overview on erythromycin genotoxicity. Indian Journal of Research in Pharmacy and Biotechnology. 2014; 2: 1348.
20. Rocídel Pilar López Panqueva. Morphological Issues of the Drug Induced Liver Disease. Continued education in hepatopathology. Revista colombiana de Gastroenterología 2014; 29: 439-50.
21. Abdel-Daim MM. Pharmacodynamic interaction of *Spirulina platensis* with Erythromycin in Egyptian Baladi bucks (*Capra hircus*). Small Ruminant Research. 2014; 120: 234-41. doi: 10.1016/j.smallrumres.2014.05.013
22. Giovanni Taranto, Matteo Nicola Dario Diminno, Domenico Capone. Drug induced liver injury. World journal gastroentrol. 2009; 15: 817-33.
23. Anne M Larson, Marshall M Kaplan, Anne C Travis. Drugs and the liver pattern of drug induced liver injury. Available at [eursoenarm.net/update/contents/mobipreview.html](http://eursoenarm.net/update/contents/mobipreview.html) 32/58/33697.
24. Kallappa SG, Jambilingappa LK. Evaluation of hepatoprotective activity of aqueous extract of *Azadirachta indica* (neem) leaves against paracetamol induced hepatotoxicity in albino rats. Pharmacologyonline. 2011; 2: 96-108.
25. Idu MD, Uvo OO, Okojei SO. Protective effect of neem (*Azadirachta Indica*) seed oil on carbon tetrachloride-induced hepatotoxicity in wistar rats. Journal of medicinal plant for economic development 2017; 1: 35-3.
-